

Breast Reconstruction The DIEP Flap

Cliff Cannon III, M.D.

Breast cancer is the most common cancer among women, excluding nonmelanoma skin cancers. Fortunately, the majority of patients affected by breast cancer are candidates for *conservative therapy*. This therapy involves the removal of a portion of the breast (lumpectomy) followed by radiation therapy. Patients who require mastectomy are candidates for reconstruction. Unfortunately the overwhelming majority seldom pursue this option. The low percentage of reconstructions has been attributed to a lack of awareness and access. Breast reconstruction does not affect the oncologic safety of breast cancer management. There is no increase in local recurrence rates and initiation of adjuvant therapy (such as chemotherapy) is not delayed. A natural appearing breast is helpful to complete the healing process both physically and psychologically. Otherwise, the lack of a breast and scar remain a reminder of the diagnosis. The current state of the art can provide a return to normalraiment and full activities with restoration of beauty and femininity.

The introduction of the pedicled transverse rectus abdominus myocutaneous (TRAM) flap by Hartrampf in 1982 used the patient's own tissue to rebuild the breast. It revolutionized post-mastectomy reconstruction by offering a reliable autogenous (using the patient's own tissue) breast reconstruction. It has been the surgery of choice for almost thirty years. However, the TRAM has its shortcomings. The pedicled Transverse Rectus Abdominis Musculocutaneous (TRAM) flap involves full muscle sacrifice, leaving a weakness to the anterior abdominal wall. Therefore, the

TRAM almost always requires implanting mesh or acellular cadaveric dermis (basic skin matrix from cadavers) at the donor site. The TRAM's blood supply, the superior epigastric (upper middle section of the abdomen) vessels, are less robust than other donor vessels.

The art of breast reconstruction has undergone revolutionary changes over the last 15 years; namely, through the advent of perforator flaps. Perforator flaps, originally pioneered by Dr. Isao Koshima, of Japan in 1989, have provided the next significant step in the field. Perforator flap reconstructions use autologous tissue reconstruction with reduced donor-site morbidity. The necessary skin, redundant soft tissue, and feeding blood vessels are removed, usually from the abdomen while leaving the rectus abdominus muscle and fascia intact. This tissue, with its blood vessels, is reattached using a high magnification microscope to recipient vessels at the mastectomy site, typically the internal mammary vessels. The final result is living, durable, and eliminates concerns for artificial materials (saline/silicone implants), and muscle sacrifice. The abdominal donor site is left with an improved contour, much like a tummy tuck.

Popularized and pioneered in New Orleans, where I trained, the Deep Inferior Epigastric Perforator (DIEP) flap was the first perforator flap used for breast reconstruction; the most significant step towards the goal of matching "like with



Cliff Cannon III, M.D.

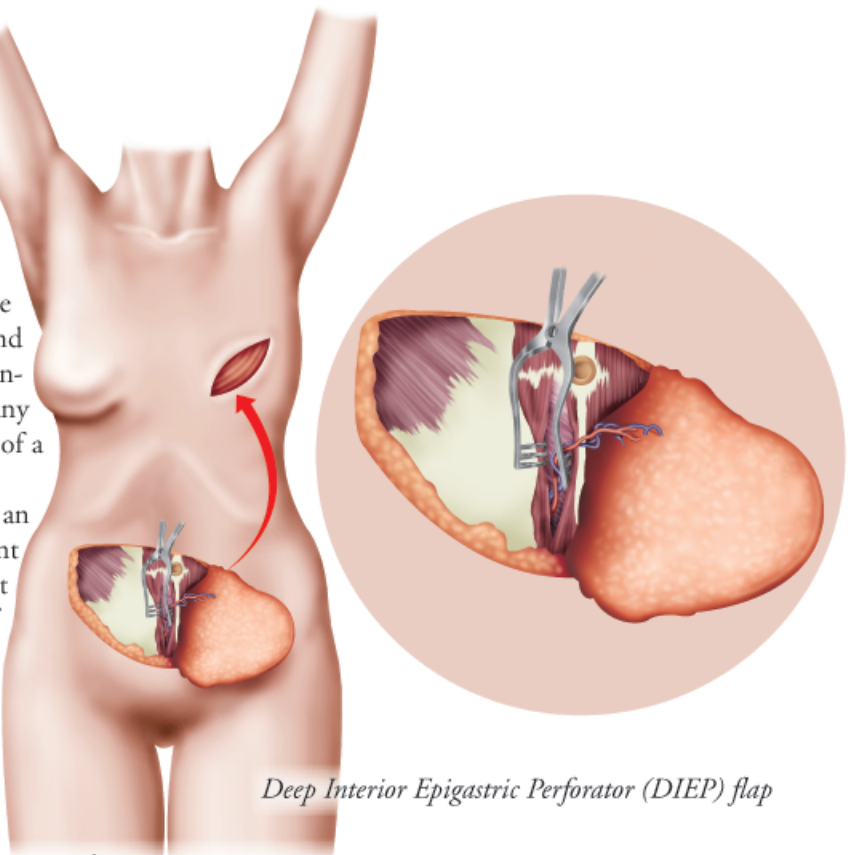
like.” Surgeons recognized that the ideal material for reconstruction of a breast is fat and skin, sparing the rectus muscle and fascia entirely, thus decreasing the abdominal donor-site morbidity encountered with a full-muscle TRAM flap. The benefits have been widely published in the literature and include reduced postoperative pain, less abdominal wall weakness, and a faster recovery. This decrease in postoperative morbidity has resulted in shorter hospital stays and cost savings by the healthcare system. By maintaining an intact rectus muscle and sheath, many published series have confirmed the presumption of a decreased hernia and bulge rate.

Autogenous tissue reconstruction may be an appropriate consideration for patients who present with an unsatisfactory or previously failed implant reconstruction. With the increased incidence of bilateral mastectomy for prophylactic indications in young patients, breast reconstruction with implants appears less reliable and has a higher failure rate. The non-autologous reconstructions shortcomings are especially pronounced when related to the morbidity and the unpredictable outcome following radiation treatment. For those with deformities or volume loss due to prior lumpectomy, radiation, or subcutaneous mastectomy, autogenous tissue reconstruction is one of the options available for restoring form. Congenital breast absence or underdevelopment may also be corrected with soft tissue perforator flap techniques.

Patients are required to be sufficiently healthy to tolerate major surgery. Significant cardiac disease, poorly controlled diabetes, COPD, or morbid obesity increases risk for complications. Advanced age, when examined as an independent variable, has not been shown to adversely affect outcomes. The primary contraindication of the deep inferior epigastric perforator (DIEP) flap is a prior intervention that would have damaged the vessels that perforate the rectus sheath (ie, abdominoplasty). Prior cesarean delivery, hysterectomy, and cholecystectomy are not contraindications.

Smokers demonstrated a significantly higher rate of complications when undergoing breast reconstruction by any method currently offered. An absolute minimum of six weeks of smoking cessation is recommended before, and after surgery. Wound healing complications after any surgery is much more frequent in patients who smoke, and the incidence of fat necrosis within the reconstructed breast is also higher. Morbid obesity has been shown to result in more frequent healing problems at the abdominal donor site. Moderately obese patients fare as well as those who are not obese.

Comprehensive, multi-specialty approach is now the



Deep Inferior Epigastric Perforator (DIEP) flap

standard of care in management of patients affected by breast cancer. The breast care nurse is a critical element of the team. She acts as a link between specialists, and provides support from the time of diagnosis until completion of reconstruction. For example, the breast care nurse can introduce the patient to women who have previously undergone reconstruction. This support network can help the patient make the correct choice among restorative options. Thus, the need for revision from unsatisfactory results will be reduced, and the process of informed consent begins.

Patients who are given the choice between muscle loss and preservation, will invariably choose preservation, most commonly the DIEP flap. The DIEP flap can carry the same tissue as the TRAM, without the sacrifice of the rectus muscle. The current standard offers a technique that would replace the breast with tissue of similar texture, optimally producing an aesthetic result indistinguishable from the natural breast. The TRAM flap leaves a dual need for improving autologous breast reconstructions: decreasing abdominal wall morbidity while improving aesthetic results. The deep inferior epigastric perforator (DIEP) flap responds well to both these challenges.

For more information on the DIEP flap procedure, Dr. Cannon may be reached at Coastal Empire Plastic Surgery, located at 900 Mohawk Street # A, Savannah, GA 31419 or you may call him at (912) 920-2090.